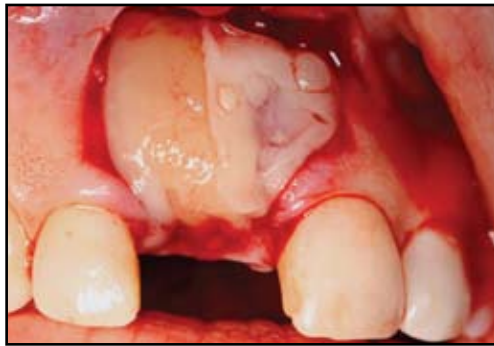

JIACD Continuing Education

Introducing Choukroun's Platelet Rich Fibrin (PRF) to the Reconstructive Surgery Milieu

Michael Toffler, DDS¹ • Nicholas Toscano, DDS, MS² • Dan Holtzclaw, DDS, MS³
Marco Del Corso, DDS, DIU⁴ • David Dohan Ehrenfest, DDS, MS, PhD⁵

Abstract



Platelet-rich fibrin (PRF), developed in France by Choukroun et al (2001), is a second generation platelet concentrate widely used to accelerate soft and hard tissue healing. Its advantages over the better known platelet-rich plasma (PRP) include ease of preparation/application, min-

imal expense, and lack of biochemical modification (no bovine thrombin or anticoagulant is required). PRF is a strictly autologous fibrin matrix containing a large quantity of platelet and leukocyte cytokines. This article serves as an introduction to the PRF “concept” and its potential clinical applications.

KEY WORDS: Platelet rich fibrin, platelet rich plasma, autologous growth factors

1. Private Practice limited to Periodontics, New York, NY, USA
2. Private Practice limited to Periodontics, Washington DC, USA
3. Private Practice limited to Periodontics, Austin, TX, USA
4. Private Practice, Department of Periodontics, Turin University, Turin, Italy
5. Researcher, Department of Biomaterials, Institute for Clinical Sciences, The Sahlgrenska Academy at University of Gothenburg, Gothenburg, Sweden

This article provides 2 hours of continuing education credit.

Please click here for details and additional information.

Learning Objectives

After reading this article, the reader should be able to:

1. Discuss the science behind Platelet Rich Fibrin.
2. Discuss how Platelet Rich Fibrin is prepared.
3. Discuss how Platelet Rich Fibrin might enhance surgical healing.

INTRODUCTION

Reconstructive dental surgeons are constantly looking for an “edge” that jump starts the healing process to maximize predictability as well as the volume of regenerated bone. Is it bone morphogenetic protein-2 (BMP-2), recombinant platelet derived growth factor-BB (rhPDGF-BB), platelet rich plasma (PRP), plasma rich in growth factors (PRGF), or a combination of all four? Let me say from the outset, “I don’t know” and this report will not provide the answer, but it will serve to introduce a second generation platelet concentrate, platelet-rich fibrin (PRF). PRF is easy to obtain, less costly, and a possibly very beneficial ingredient to add to the “regenerative mix.”

Pre-implant reconstruction of the deficient alveolar ridge facilitates ideal prosthetic positioning of implants and improves the long-term success of implant-supported restorations.¹⁻³ Regardless of the choice of graft material (autograft, allograft, xenograft or alloplast) or membrane selection (bioresorbable or nonresorbable), predictable bone regeneration is dependent upon 4 major biologic principles: primary wound closure, blood supply, space maintenance, and wound stability.⁴ Bone grafting is most successful when it occurs in a contained, well vas-

cularized environment, stressing the importance of primary closure and the promotion of angiogenesis.

Blood supply provides the necessary cells, growth factors, and inhibitors to initiate the osteogenic biomineralization cascade.⁵ Injury to blood vessels during oral surgical procedures causes blood extravasation, subsequent platelet aggregation, and fibrin clot formation. The major role of fibrin in wound repair is hemostasis, but fibrin also provides a matrix for the migration of fibroblasts and endothelial cells that are involved in angiogenesis and responsible for remodeling of new tissue. Platelet activation in response to tissue damage and vascular exposure results in the formation of a platelet plug and blood clot as well as the secretion of biologically active proteins.⁶ Platelet alpha (α) granules form an intracellular storage pool of growth factors (GF) including platelet-derived growth factor (PDGF), transforming growth factor β (TGF- β , including β -1 and β -2-isomers), vascular endothelial growth factor (VEGF), and epidermal growth factor (EGF).⁷ Insulin-like growth factor-1 (IGF-1), which is present in plasma, can exert chemotactic effects towards human osteoblasts.⁸ After platelet activation, α granules fuse with the platelet cell membrane transforming some of the secretory proteins to a bioactive state.^{9,10} Active proteins are secreted and bind to transmembrane receptors of target cells to activate intracellular signaling proteins.¹¹ This results in the expression of a gene sequence that directs cellular proliferation, collagen synthesis, and osteoid production.¹²

Platelet Rich Plasma

Several studies have shown that bone regenerative procedures may be enhanced by the addition of specific growth factors.^{13,14} Platelet-rich plasma (PRP) was proposed as a method of

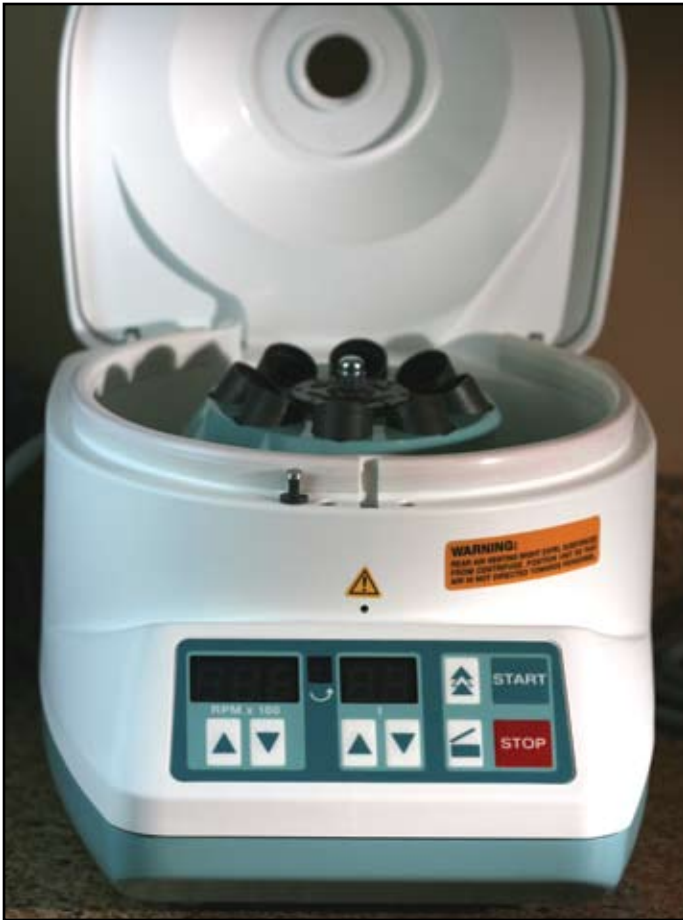

Figure 1: Process® centrifuge.

introducing concentrated growth factors PDGF, TGF- β , and IGF-1 to the surgical site, enriching the natural blood clot in order to expedite wound healing and stimulate bone regeneration.¹⁵ A natural human blood clot contains 95% red blood cells (RBCs), 5% platelets, less than 1% white blood cells (WBCs), and numerous amounts of fibrin strands. A PRP blood clot, on the other hand, contains 4% RBCs, 95% platelets, and 1% WBCs.¹⁶ The classic PRP production protocol requires blood collection with anticoagulant, 2 steps of centrifuga-

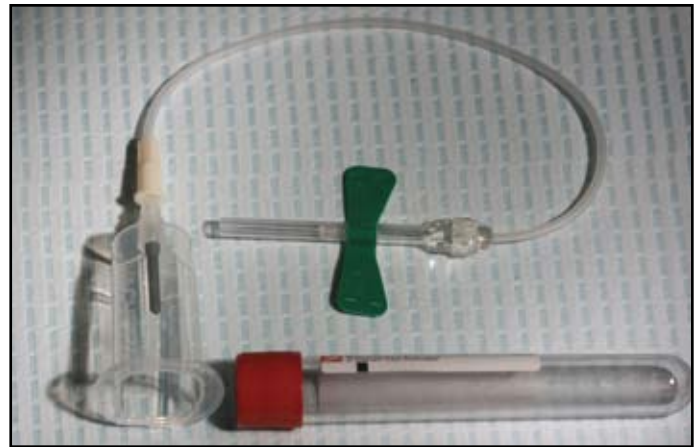


Figure 2: PRF collection kit including 24 gauge butterfly needle and 9 ml blood collection tube.




Figure 3: Single spin produces 3 layers: top is platelet poor plasma, middle is PRF, and bottom layer contains red blood cells (RBC's).

tion, and artificial polymerization of the platelet concentrate using calcium chloride and bovine thrombin.^{17,18} Since its introduction, PRP has been used in conjunction with different grafting materials in bone augmentation procedures.¹⁹⁻²³ To date, the results from these studies are controversial and no conclusions can be drawn regarding the bone regenerative effect of PRP.⁶

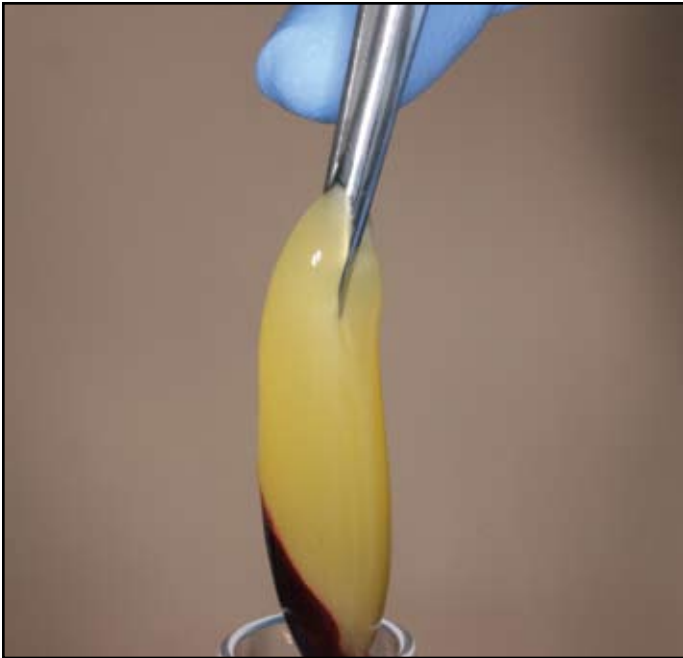


Figure 4: Pliers are inserted into the tube to gently grab the fibrin clot with attached RBC's.

Platelet Rich Fibrin

Platelet-rich fibrin (PRF) represents a new step in the platelet gel therapeutic concept with simplified processing minus artificial biochemical modification.²⁴ Unlike other platelet concentrates,^{17,18} this technique requires neither anticoagulants nor bovine thrombin (nor any other gelifying agent), making it no more than centrifuged natural blood without additives. Developed in France by Choukroun et al in 2001,²⁵ the PRF production protocol attempts to accumulate platelets and released cytokines in a fibrin clot. Though platelets and leukocyte cytokines play an important part in the biology of this biomaterial, the fibrin matrix supporting them certainly constitutes the determining element responsible for the real therapeutic potential of PRF.²⁴⁻²⁸ Cytokines are quickly used and destroyed in a healing wound. The synergy between cytok-

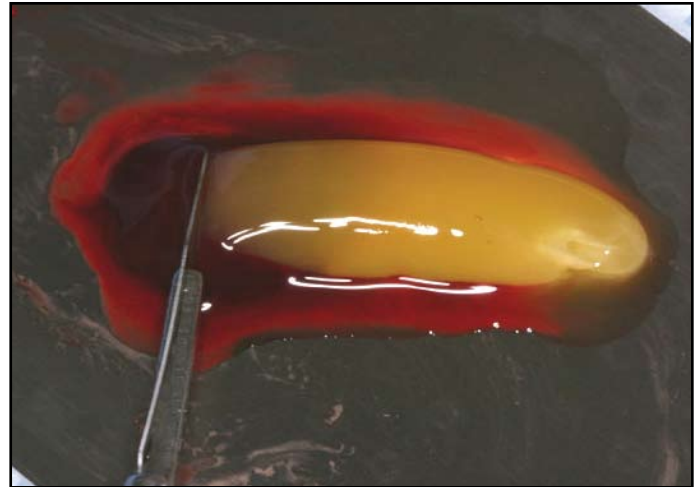


Figure 5: Fibrin clots are transferred to sterile metal surface and RBCs are gently scraped away and discarded.

ines and their supporting fibrin matrix has much more importance than any other parameter. A physiologic fibrin matrix (such as PRF) will have very different effects than a fibrin glue enriched with cytokines (such as PRP), which will have a massively uncontrollable and short-term effect.

Preparation and Clinical Applications of PRF

PRF preparation requires an adequate table centrifuge (figure 1), (PC-02, Process Ltd., Nice, France), and collection kit including: a 24 gauge butterfly needle and 9 ml blood collection tubes (figure 2). The protocol for PRF preparation is very simple: whole blood is drawn into the tubes without anticoagulant and is immediately centrifuged. Within a few minutes, the absence of anticoagulant allows activation of the majority of platelets contained in the sample to trigger a coagulation cascade. Fibrinogen is at first concentrated in the upper part of the tube, until the effect of the circulating thrombin transforms it into a fibrin network. The result is a fibrin clot containing the platelets located in the




Figure 6: PRF is placed on the grid in the PRF Box®.

middle of the tube, just between the red blood cell layer at the bottom and acellular plasma at the top (figure 3). Unlike PRP, the PRF results from a natural and progressive polymerization which occurs during centrifugation. This clot is removed from the tube and the attached red blood cells scraped off and discarded (figures 4,5). The PRF clot (figure 6) is then placed on the grid in the PRF Box® (figure 7) (Process Ltd., Nice, France), and covered




Figure 7: Complete PRF Box® set up.

with the compressor and lid. This produces an inexpensive autologous fibrin membrane in approximately one minute (figure 8). The PRF Box® was devised to produce membranes of constant thickness that remain hydrated for several hours and to recover the serum exudate expressed from the fibrin clots which is rich in the proteins vitronectin and fibronectin.²⁶ The exudate collected at the bottom of the box may be used to hydrate graft materials, rinse the surgical site, and store autologous grafts.

Concerning specific procedures, PRF membranes may be utilized in combination with graft materials to expedite healing in lateral sinus floor elevation.²⁹ Choukroun et al²⁹ evaluated the potential of PRF in combination with freeze-dried bone allograft (FDBA) to enhance bone regeneration in lateral sinus floor elevation. Nine sinus floor augmentations were performed with 6 sinuses receiving PRF + FDBA particles (test group) and 3 sinuses receiving FDBA without PRF (control group). Four months after implantation (test group) and 8 months later (control), bone specimens were



Figure 8: PRF Box[®] is used to create PRF membranes. Serum exudate collects in the bottom of the box beneath the grid.

harvested with a 3mm diameter trephine during implant insertion. Histologic evaluations revealed the presence of residual bone particles surrounded by newly formed bone and connective tissue. At 4 months, the histologic maturation of the test group appeared identical to that of the control group after a period of 8 months with the quantities of newly formed bone equivalent between the two protocols. The use of PRF in combination with FDBA to perform sinus floor augmenta-

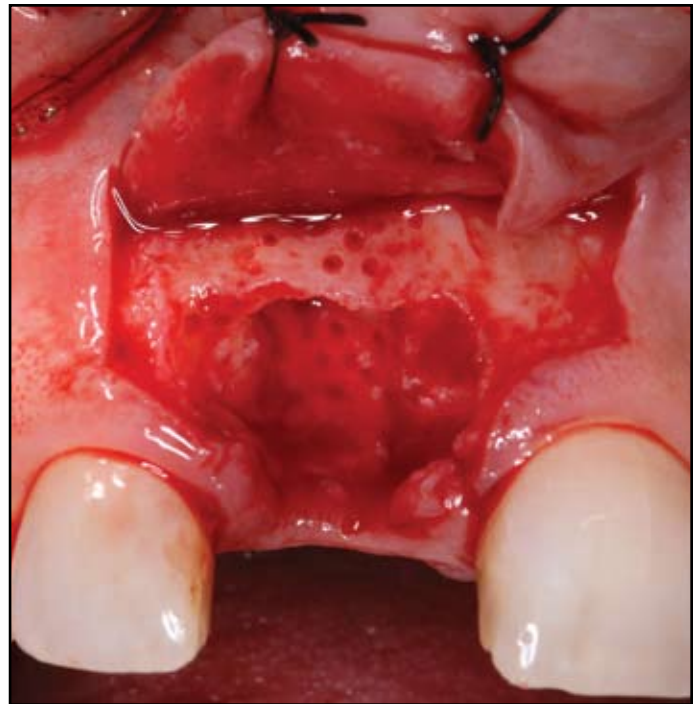


Figure 9: Residual defect after extraction of fractured #8.

tion seemed to accelerate bone regeneration.

When performing ridge augmentation, PRF membranes are used to protect and stabilize the graft materials (figures 9-11). The membranes act as fibrin bandages, accelerating the healing of the soft tissues, facilitating the rapid closure of the incision despite a substantial volume of added bone (figures 12-14). In a two-part publication, Simonpieri et al^{30,31} reported on a new technique for maxillary reconstruction using FDBA, PRF membranes and 0.5% metronidazole solution. A small quantity of a 0.5% metronidazole solution (10 mg) was used to provide an efficient protection of the bone graft against unavoidable bacterial contamination.³² PRF membranes were used to protect the surgical site and foster soft tissue healing and PRF fragments were mixed with the graft

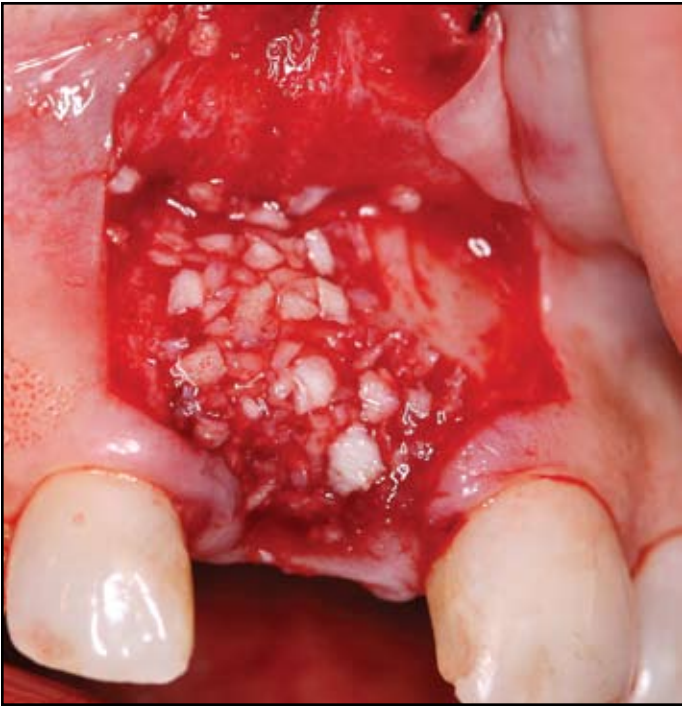

Figure 10: Defect grafted with Regenaform (RTI Biologics, Alachua, FL).

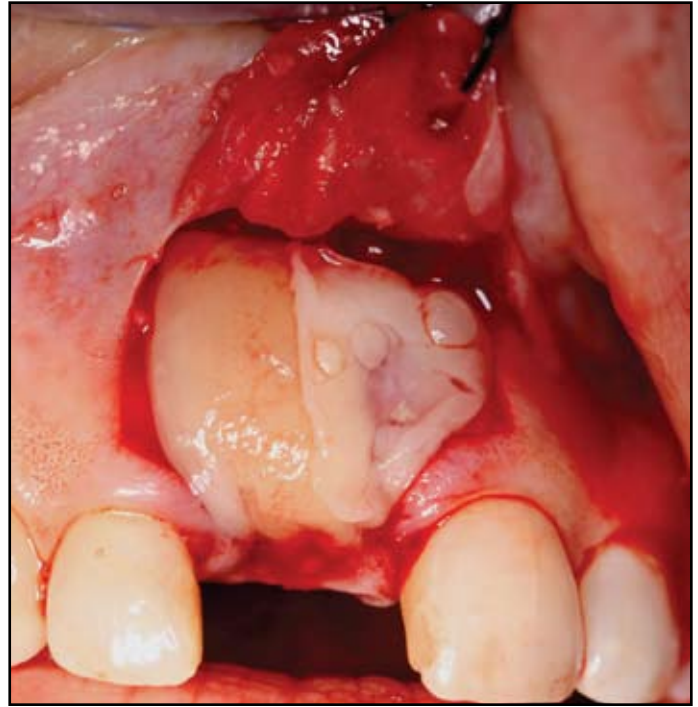


Figure 11: Graft is covered with 2 to 4 PRF membranes.

particles. The membranes may be cut into few-millimeter fragments and mixed with the graft material (figures 15,16), functioning as a “biological connector” between the different elements of the graft, and as a matrix which favors neo-angiogenesis, the capture of stem cells, and the migration of osteoprogenitor cells to the center of the graft.^{5,6} Using the reported protocol, they consistently observed a high degree of gingival maturation after healing with a thickening of keratinized gingival tissues that improved the esthetic integration and final result of their prosthetic rehabilitations. In addition, all their clinical experiences emphasized that the use of PRF seemed to reduce postoperative pain and edema, and limited even minor infectious phenomena.³¹

To get thick small discs or “plugs” of PRF, useful in protecting extraction sites, the PRF clot is

placed into the cylinder in the PRF Box[®] and slowly compressed with the piston (figures 17-19). The small discs measure 1 cm in diameter and are easily inserted into residual extraction defects to expedite soft tissue healing in site preservation procedures permitting ideal prosthetic implant placement (figure 20). PRF plugs are also positioned in the implant osteotomy to facilitate sinus floor elevation using a crestal core elevation (CCE) procedure³³ or osteotome-mediated sinus floor elevation (OMSFE) with simultaneous implant placement.³⁴ Diss et al³⁵ documented radiographic changes in the apical bone levels on 20 patients with 35 microthreaded implants placed using OMSFE with PRF as the sole grafting material. Despite a limited residual subantral bone height (RSBH) of 4.5 to 8 mm, a healing period of 2-3 months

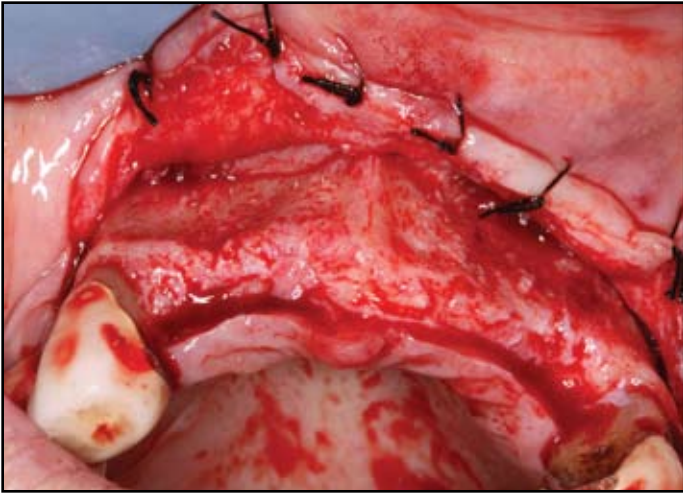


Figure 12: Narrow alveolar ridge in anterior maxilla.

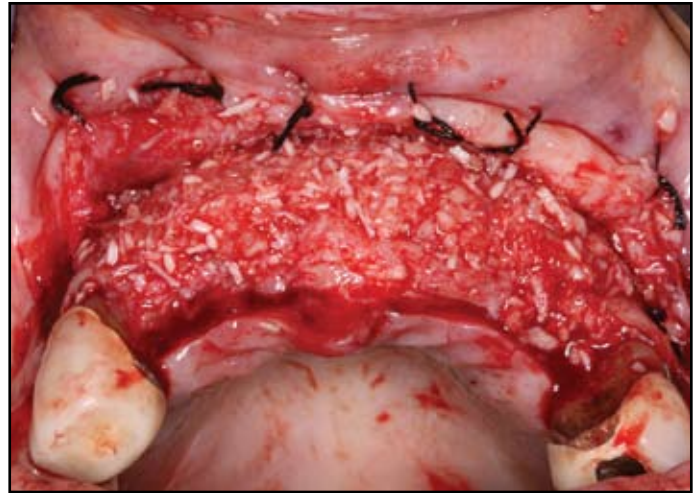


Figure 13: Buccal defects grafted with FDBA (LifeNet, Virginia Beach, VA).

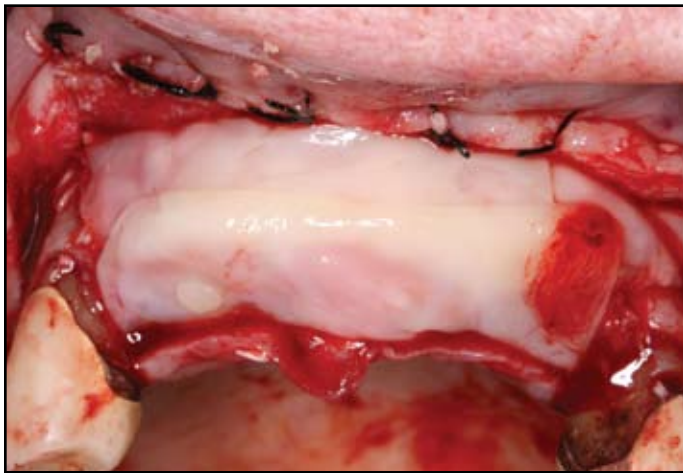


Figure 14: Complete coverage of graft and crest with 4 to 6 PRF membranes.

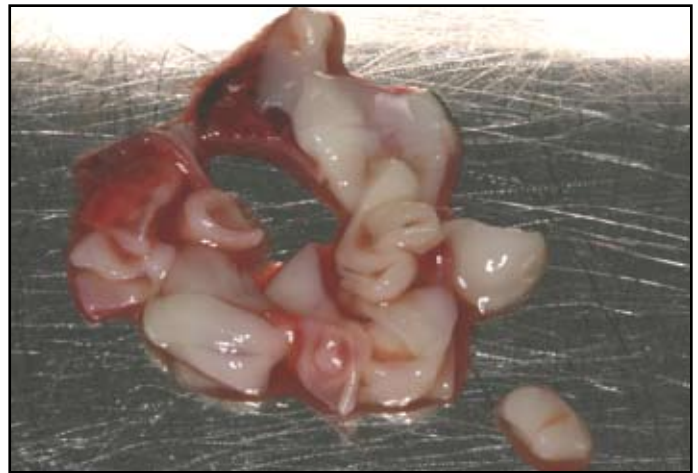

Figure 15: PRF membrane has been fragmented to mix easily with graft material.

was found to be sufficient to resist a torque of 25 Ncm applied during abutment tightening. One implant failed during the initial healing, but at one year, 34/35 implants were clinically stable and the definitive prostheses were in function, resulting in a survival rate of 97.1%. The mean endosinus bone gain was 3.2 mm with radiographic documentation of apical displacement of the sinus floor. Not

only can PRF be used in lieu of particulate grafting to predictably elevate the sinus floor using a crestal approach, but the PRF membrane can provide protection for the sinus membrane during the use of an osteotome, and in case of perforation, the fibrin matrix can aid in wound closure.^{35,36} The authors always utilize PRF membranes in the lateral window osteotomy procedure to line the

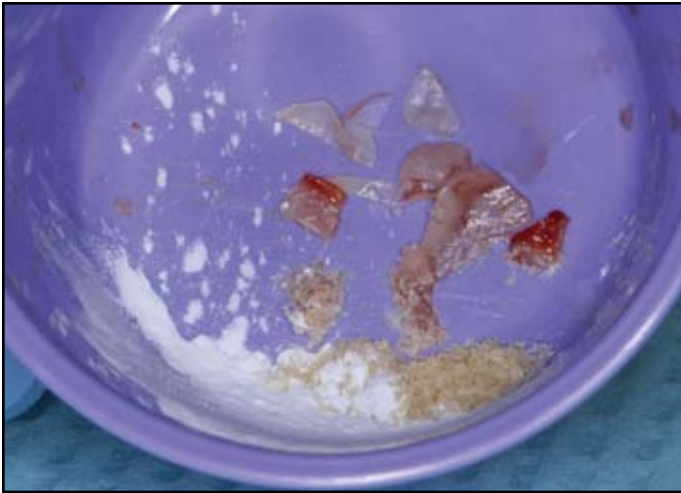


Figure 16: “Extraction Mix” – PRF fragments + FDBA + calcium sulfate (Ace Surgical, Brockton, MA).



Figure 17: PRF has been placed into cylinders in the PRF Box®.



Figure 18: Pistons are used to gently compress PRF.

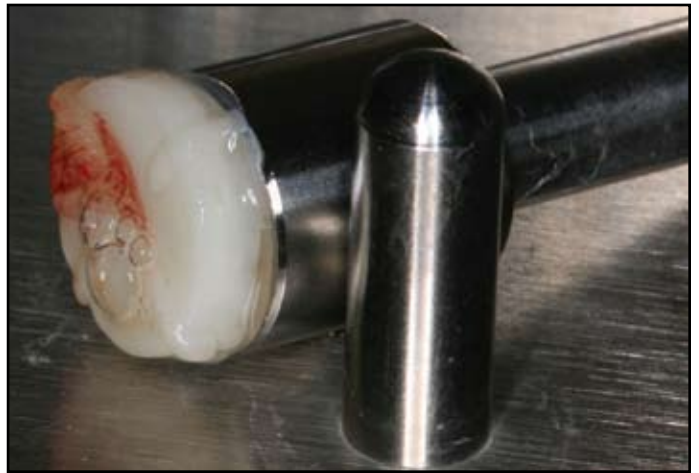

Figure 19: Compression results in the formation of a PRF plug.

membrane prior to grafting as “membrane insurance” possibly sealing an undetected perforation which can lead to serious postoperative sequelae.

DISCUSSION

PRF is a matrix of autologous fibrin, in which are embedded a large quantity of platelet and leukocyte cytokines during centrifugation.^{24,25} The

intrinsic incorporation of cytokines within the fibrin mesh allows for their progressive release over time (7-11 days), as the network of fibrin disintegrates.³⁰ The easily applied PRF membrane acts much like a fibrin bandage,⁵ serving as a matrix to accelerate the healing of wound edges.¹¹ It also provides a significant postoperative protection of the surgical site and seems to accelerate the

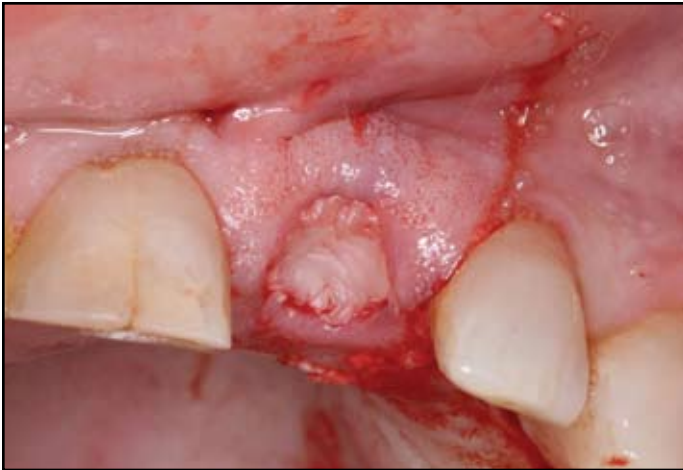

Figure 20: PRF plug has been placed in grafted socket immediately after removal of fractured #9.

integration and remodeling of the grafted biomaterial.²⁵⁻²⁷ According to Simonpieri et al,³¹ the use of this platelet and immune concentrate during bone grafting offers the following 4 advantages: First, the fibrin clot plays an important mechanical role, with the PRF membrane maintaining and protecting the grafted biomaterials and PRF fragments serving as biological connectors between bone particles. Second, the integration of this fibrin network into the regenerative site facilitates cellular migration, particularly for endothelial cells necessary for the neo-angiogenesis,²⁴ vascularization and survival of the graft. Third, the platelet cytokines (PDGF, TGF- β , IGF-1) are gradually released as the fibrin matrix is resorbed, thus creating a perpetual process of healing.^{20,30} Lastly, the presence of leukocytes and cytokines in the fibrin network can play a significant role in the self-regulation of inflammatory and infectious phenomena within the grafted material.²¹

CONCLUSION

Early publications and clinical experience seem to indicate that PRF improves early wound closure, maturation of bone grafts, and the final esthetic result of the peri-implant and periodontal soft tissues. Additional reports are forthcoming, highlighting the many clinical applications and healing benefits of this second generation platelet concentrate. ●

Professional Dental Education and Professional Education Services Group are joint sponsors with The Academy of Dental Learning in providing this continuing dental education activity.

The Academy of Dental Learning is an ADA CERP Recognized Provider. The Academy of Dental Learning designates this activity for two hours of continuing education credits.

ADA CERP is a service of the American Dental Association to assist dental professionals in identifying quality providers of continuing dental education. ADA CERP does not approve or endorse individual courses or instructors, nor does it imply acceptance of credit hours by boards of dentistry

Correspondence:

Michael Toffler, D.D.S.
Diplomate American Board of Periodontology
116 Central Park South, Suite 3
New York New York 10019
mtoffler@earthlink.net

Disclosure

The authors report no conflicts of interest with anything mentioned in this article.

References

1. Raghoobar GM, Timmenga NM, Reintsema H, et al. Maxillary bone grafting for insertion of endosseous implants: Results after 12–124 months. *Clin Oral Implants Res* 2001; 12:279-286.
2. Wallace SS, Froum SJ. Effect of maxillary sinus augmentation on the survival of endosseous dental implants. A systematic review. *Ann Periodontol* 2003; 8:328-343.
3. Tulasne JF. [Commentary on maxillary pre-implant rehabilitation. A study of 55 cases using autologous bone graft augmentation]. *Rev Stomatol Chir Maxillofac* . 1999; 100:265-266.
4. Wang HL, Boyapati L. "PASS" principles for predictable bone regeneration. *Implant Dent* 2006; 15(1):8-17.
5. Vence BS, Mandelaris GA, Forbes DP. Management of dentoalveolar ridge defects for implant site development: An interdisciplinary approach. *Compend Cont Ed Dent* 2009; 30(5):250-262.
6. Hamdan AA-S, Loty S, Isaac J, Bouchard P, Berdal A, Sautier J-M. Platelet-poor plasma stimulates proliferation but inhibits differentiation of rat osteoblastic cells in vitro. *Clin Oral Impl Res* 2009; 20:616-623.
7. Su CY, Kuo YP, Tseng YH, Su C-H, Burnouf T. In vitro release of growth factors from platelet-rich fibrin (PRF): a proposal to optimize the clinical applications of PRF. *Oral Surg Oral Med Oral Pathol Oral Radiol Endod* 2009; 108:56-61.
8. Lind M. Growth factor stimulation of bone healing. Effects on osteoblasts, osteomies, and implants fixation. *Acta Orthop Scand Suppl* 1998; 283:2-37.
9. White JG, Krumwiede M. Further studies of the secretory pathway in thrombin-stimulated human platelets. *Blood* 1987; 69:1196-1203.
10. Zucker-Franklin D, Benson KA, Myers KM. Absence of a surface-connected canalicular system in bovine platelets. *Blood* 1985; 65:241-244.
11. Gaßling VLW, Açıly, Springer IN, Hubert N, Wiltfang J. Platelet-rich Plasma and Platelet-rich fibrin in human cell culture. *Oral Surg Oral Med Oral Pathol Oral Radiol Endod* 2009; 108:48-55.
12. Marx RE. Platelet-rich plasma: evidence to support its use. *J Oral Maxillofac Surg* 2004; 62:489-496.
13. Jung RE, Glauser R, Scharer P, Hammerle CH, Sailer HF, Weber FE. Effect of rh-BMP-2 on guided bone regeneration in humans. *Clin Oral Implants Research* 2003; 14:556-568.
14. Nevins, M, Giannobile WV, McGuire MK, Kao RT, Mellonig JT, Hinrichs JT, et al. Platelet-derived growth factor stimulates bone fill and rate of attachment level gain: Results of a large multicenter randomized controlled trial. *J Periodontol* 2005;76:2205-2215.
15. Soffer E, Ouhayoun JP, Anagnostou F. Fibrin sealants and platelet preparations in bone and periodontal healing. *Oral Surg Oral Med Oral Pathol Oral Radiol Endod* 2003; 95:521-528.
16. Sunitha RV, Munirathnam NE. Platelet – Rich Fibrin: Evolution of a second-generation platelet concentrate. *Indian J Dent Res* 2008; 19(1):42-46.
17. Marx RE, Carlson ER, Eichstaedt RM, Schimmele SR, Strauss JE, Georgeff KR. Platelet-rich plasma: Growth factor enhancement for bone grafts. *Oral Surg Oral Med Oral Pathol Oral Radiol Endod* 1998; 85(6):638-646.
18. Weibrich G, Kleis WK, Buch R, Hitzler WE, Hafner G. The Harvest Smart PRP system versus the Friadent-Schutze platelet-rich plasma kit. *Clin Oral Implants Res* 2003; 14:233-239.
19. Wiltfang J, Schlegel KA, Schultze-Mosgau S, Nkenke E, Zimmermann R, Kessler P. Sinus floor augmentation with beta-tricalcium phosphate (beta-TCP): Does platelet-rich plasma promote its osseous integration and degradation? *Clin Oral Implants Res* 2003; 14:213-218.
20. Mazor Z, Peleg M, Garg AK, Luboshitz J. Platelet-rich plasma for bone graft enhancement in sinus floor augmentation with simultaneous implant placement: patient series study. *Implant Dent* 2004; 13:65-72.
21. Froum SJ, Wallace SS, Tarnow DP, Cho SC. Effect of platelet-rich plasma on bone growth and osseointegration in human maxillary sinus grafts: Three bilateral case reports. *Int J Periodontics Restorative Dent* 2002; 22:45-53
22. Kassolis JD, Rosen PS, Reynolds MA. Alveolar ridge and sinus augmentation utilizing platelet-rich plasma in combination with freeze-dried bone allograft: case series. *J Periodontol* 2000; 71:1654-1661.
23. Sanchez AR, Sheridan PJ, Kupp LI. Is platelet-rich plasma the perfect enhancement factor? A current review. *Int J Oral Maxillofac Implants* 2003; 18:93-103.
24. Dohan DM, Choukroun J, Diss A, Dohan SL, Dohan AJ, Mouhyi J, Gogly B. Platelet-rich fibrin (PRF): a second-generation platelet concentrate. Part I: technological concepts and evolution. *Oral Surg Oral Med Oral Pathol Oral Radiol Endod* 2006; 101:e37-44.
25. Choukroun J, Adda F, Schoeffler C, Vervelle A. Une opportunité en paro-implantologie: le PRF. *Implantodontie* 2001; 42:55-62.
26. Dohan DM, Choukroun J, Diss A, Dohan SL, Dohan AJ, Mouhyi J, Gogly B. Platelet-rich fibrin (PRF): a second-generation platelet concentrate. Part II: platelet-related biologic features. *Oral Surg Oral Med Oral Pathol Oral Radiol Endod* 2006; 101:e45-50.
27. Dohan DM, Choukroun J, Diss A, Dohan SL, Dohan AJ, Mouhyi J, Gogly B. Platelet-rich fibrin (PRF): A second generation platelet concentrate. III. Leukocyte activation: A new feature for platelet concentrates? *Oral Surg Oral Med Oral Pathol Oral Radiol Endod* 2006; 101:e51-55.
28. Choukroun J, Diss A, Simonpieri A, Girard MO, Schoeffler C, et al. Platelet-rich fibrin (PRF): a second-generation platelet concentrate. Part IV: clinical effects on tissue healing. *Oral Surg Oral Med Oral Pathol Oral Radiol Endod* 2006; 101:e56-60.
29. Choukroun J, Diss A, Simonpieri A, Girard M-O, Schoeffler C, et al. Platelet-rich fibrin (PRF): A second generation platelet concentrate. Part V: Histologic evaluations of PRF effects on bone allograft maturation in sinus lift. *Oral Surg Oral Med Oral Pathol Oral Radiol Endod* 2006;101: 299-303.
30. Simonpieri A, Del Corso M, Sammartino G, Dohan Ehrenfest DM. The Relevance of Choukroun's Platelet-Rich Fibrin and Metronidazole during Complex Maxillary Rehabilitations Using Bone Allograft. Part I: A New Grafting Protocol. *Implant Dent* 2009; 18:102–111.
31. Simonpieri A, Del Corso M, Sammartino G, Dohan Ehrenfest DM. The Relevance of Choukroun's Platelet-Rich Fibrin and Metronidazole during Complex Maxillary Rehabilitations Using Bone Allograft. Part II: Implant Surgery, Prosthodontics, and Survival. *Implant Dent* 2009; 18:220–229.
32. Choukroun J, Simonpieri A, Del Corso M, Mazor, Z, Sammartino, G, Dohan Ehrenfest, DM. Controlling systematic perioperative anaerobic contamination during sinus-lift procedures by using metronidazole: An innovative approach. *Implant Dent* 2008; 17:257-270.
33. Toffler M. Staged sinus augmentation using a crestal core elevation procedure (CCE) to minimize membrane perforation. *Pract Proced Aesthet Dent* 2002; 14:767–774.
34. Toffler, M. Osteotome-mediated sinus floor elevation: A clinical report. *Int J Oral Maxillofac Implants* 2004; 19:266–273.
35. Diss A, Dohan DM, Mouhyi J, Mahler P. Osteotome sinus floor elevation using Choukroun's platelet-rich fibrin as grafting material: A 1-year prospective pilot study with microthreaded implants. *Oral Surg Oral Med Oral Pathol Oral Radiol Endod* 2008; 105:572-579.
36. Choi BH, Zhu SJ, Jung JH, Lee SH, Huh JY. The use of autologous fibrin glue for closing sinus membrane perforations during sinus lifts. *Oral Surg Oral Med Oral Pathol Oral Radiol Endod* 2006; 101:150-154.

FOR 2 HOURS CE CREDIT TAKE THE QUIZ ON THE NEXT PAGE



Continuing Education JACD Quiz #2

- 1. Predictable bone regeneration is dependent upon which major biologic principles?**
 - a. Primary wound closure
 - b. Blood supply
 - c. Space maintenance and wound stability
 - d. All of the above
- 2. The major role of fibrin in wound repair is hemostasis.**
 - a. True
 - b. False
- 3. Platelet activation in response to tissue damage and vascular exposure results in the formation of a platelet plug and blood clot as well as the secretion of biologically active proteins.**
 - a. True
 - b. False
- 4. Platelet alpha (α) granules form an intracellular storage pool of growth factors which include all the following except?**
 - a. Platelet-derived growth factor
 - b. Bone morphogenetic protein
 - c. Vascular endothelial growth factor
 - d. Epidermal growth factor
- 5. The PRF technique requires anticoagulants in order to process it.**
 - a. True
 - b. False
- 6. PRF preparation requires which of the following?**
 - a. Adequate table centrifuge
 - b. 24 gauge butterfly needle
 - c. 9 ml blood collection tubes
 - d. All of the above
- 7. The protocol for PRF preparation requires immediate centrifugation after blood collection.**
 - a. True
 - b. False
- 8. The PRF Box[®] was devised to produce:**
 - a. Membranes of constant thickness
 - b. Recovery of serum exudate
 - c. All of the above
 - d. None of the above
- 9. PRF membrane acts like a fibrin bandage, serving as a matrix to accelerate healing of soft tissues.**
 - a. True
 - b. False
- 10. PRF is a matrix of autologous fibrin, in which are embedded a large quantity of platelet and leukocyte cytokines during centrifugation.**
 - a. True
 - b. False

[CLICK HERE TO TAKE THE QUIZ](#)

